

Survival Analysis of Revision Autologous Chondrocyte Implantation for Failed ACI

Takahiro Ogura,^{*†} MD, Tim Bryant,^{*‡} BSN, RN, Gergo Merkely,^{*§} MD,
Brian A. Mosier,^{*||} MD, and Tom Minas,^{*‡¶} MD, MS

Investigation performed at the Cartilage Repair Center, Brigham and Women's Hospital, Harvard Medical School, Boston, Massachusetts, USA

Background: Autologous chondrocyte implantation (ACI) provides a successful outcome for treating articular cartilage lesions. However, there have been very few reports on the clinical outcomes of revision ACI for failed ACI.

Purpose: To evaluate clinical outcomes in patients who underwent revision ACI of the knee for failure of an initial ACI and to determine the factors affecting the survival rate.

Study Design: Case series; Level of evidence, 4.

Methods: A review of a prospectively collected data set was performed from patients who underwent revision ACI of the knee for failure of an initial ACI between 1995 and 2014 by a single surgeon. The authors evaluated 53 patients (53 knees; mean age, 38 years) over a mean 11.2-year follow-up (range, 2-20). A total of 62 cartilage lesions were treated for failed graft lesions after an initial ACI, and 31 new cartilage lesions were treated at revision ACI, as there was progression of disease. Overall, 93 cartilage lesions (mean, 1.8 lesions per knee) with a total surface area of 7.4 cm² (range, 2.5-18 cm²) per knee were treated at revision ACI. Survival analysis was performed with the Kaplan-Meier method, with ACI graft failure or conversion to a prosthetic arthroplasty as the endpoint. The modified Cincinnati Knee Rating Scale, Western Ontario and McMaster Universities Osteoarthritis Index, visual analog scale, and 36-Item Short Form Health Survey were used to evaluate clinical outcomes. Patients also self-reported knee function and satisfaction. Standard radiographs were evaluated with Kellgren-Lawrence grades.

Results: Survival rates were 71% and 53% at 5 and 10 years, respectively. Survival subanalysis revealed a trend that patients without previous cartilage repair procedures before an initial ACI had better survival rates than those with such procedures (81% vs 62% at 5 years, 64% vs 42% at 10 years, $P = .0958$). Patients with retained grafts showed significant improvement in pain and function, with a high level of satisfaction. At a mean 5.1 years postoperatively, 18 of 27 successful knees were radiographically assessed with no significant osteoarthritis progression. Outcomes for 26 patients were considered failures (mean, 4.9 years postoperatively), in which 15 patients had prosthetic arthroplasty (mean, 4.6 years) and the other 11 patients had revision cartilage repair (mean, 5.4 years) and thus could maintain their native knees.

Conclusion: Results of revision ACI for patients who failed ACI showed acceptable clinical outcomes. Revision ACI may be an option for young patients after failed initial ACI, particularly patients without previous cartilage repair procedures and those who desire to maintain their native knees.

Keywords: autologous chondrocyte implantation; revision; articular; cartilage; repair

Articular cartilage defects are a risk factor for the development of osteoarthritis owing to the limited innate ability of cartilage to heal spontaneously.^{8,10} After the first report by Brittberg et al⁶ in 1994, autologous chondrocyte implantation (ACI) has been recognized as an established treatment for symptomatic large full-thickness chondral lesions in various populations.^{31,37,38,42} A number of studies have reported successful and durable clinical outcomes after ACI over long-term follow-up, with good to excellent outcomes in approximately 80% of patients.^{31,40} However,

failure rates for ACI, as defined by graft failure or conversion to arthroplasty, have been reported to occur in 7% to 26% of patients.^{1,4,23,31,32} For those young active patients who have had a failure of ACI and are not candidates for prosthetic arthroplasty, the next treatment choice can be a difficult decision. The variables to be considered depend on the size of the area that has failed, the reason for failure, and whether there has been progression of disease with the development of new focal cartilage lesions. These options include debridement alone, cartilage repair with marrow stimulation techniques, osteochondral autografts/allografts, revision ACI, or prosthetic arthroplasty. A careful consideration is necessary, as previous studies demonstrated that there are several factors that contribute to poor results of a cartilage repair procedure in patients who have failed prior treatment, such as age, body mass

index, size of lesions, and a history of bone marrow stimulation.^{15,16,28,34,39} To date, there have been very few reports on the outcomes after revision ACI for patients who failed initial ACI. We evaluated the clinical outcomes of patients who underwent revision ACI for failure of an initial ACI and analyzed the factors affecting the survival rate. We hypothesized that revision ACI would provide acceptable clinical outcomes and that failed cartilage repair procedures before an initial ACI would affect the outcomes after the revision ACI.

METHODS

Patient Demographics

This study was approved by the institutional review board, with written informed consent obtained from all patients when they were entered into the database. Starting in October 1995 until February 2014, a single surgeon (T.M.) treated 680 patients (692 knees) with ACI: periosteum-covered ACI (ACI-P) in 432 knees and collagen membrane-covered ACI (ACI-C) in 260 knees. A total of 144 knees (ACI-P: $n = 118$, 27.3%; ACI-C: $n = 26$, 10%) were considered treatment failures. This included graft failure in 79 knees (ACI-P in 62 and ACI-C in 17) or the development of new chondral lesions considered progression of disease in 65 knees (ACI-P in 56 and ACI-C in 9) at a mean 4.2 years postoperatively (SD, 3.7 years; range, 0.2-15.5 years). Among these 144 knees, 54 were treated with revision ACI for failure of an initial ACI with or without progression of disease; 58 knees were treated with arthroplasty owing to progression of disease; and 26 knees failed because of graft failure and were treated with osteochondral allograft transplantation in 16 knees, autologous bone grafting in 4, unloading osteotomy in 2, microfracture in 2, osteochondral autograft transplantation in 1, and OBI TruFit plugs (Smith & Nephew) transplantation in 1. The remaining 6 knees needed no further treatment. The indication for a revision ACI included focal cartilage lesions >2 cm² instead of diffuse cartilage lesions and patients who wished to maintain their native joints. Of 54 patients (54 knees) treated with revision ACI, 1 did not return for follow-up and was excluded. This study included 53 patients (53 knees) who had >2 years of follow-up at the time of data analysis. There were 26 men and 27 women. Mean age at the time of an initial ACI and revision ACI was 35 years (SD, 9.6 years; range, 18-52 years) and 38 years (SD, 9.7 years; range, 19-60), respectively. Patients were

TABLE 1
Patient Demographics^a

Variable	Mean \pm SD (Range)
Age at revision ACI, y	38 \pm 9.7 (19-60)
Body mass index, kg/m ²	27.5 \pm 5.2 (19-40)
Follow-up after revision ACI, y	11.2 \pm 4.7 (2-20)
Period between initial and revision ACI, y	3.2 \pm 2.8 (0.3-13.7)

^aACI, autologous chondrocyte implantation.

followed up after revision ACI surgery over a mean 11.2 years (SD, 4.7 years; range, 2-20 years). At the time of revision ACI surgery, all 53 patients were treated for at least 1 failed graft lesion (62 failed grafts). Additionally, 20 out of 53 patients were treated for 31 additional new cartilage lesions during revision ACI. Overall, 93 cartilage lesions (mean, 1.8 lesions per knee) with a total mean surface area of 7.4 cm² (SD, 4.1 cm²; range, 2.5-18 cm²) per knee were treated during revision ACI (Tables 1 and 2). Table 3 summarizes surgery on the cartilage lesions before the initial ACI, between the initial and revision ACI, and during the revision ACI. Before the initial ACI, 45 patients (85%) had previous knee surgery (excluding cartilage biopsy), in which 26 had undergone a mean 1.9 cartilage repair procedures and 25 had undergone a mean 1.4 noncartilage procedures, including primarily partial meniscectomy ($n = 10$), anterior cruciate ligament reconstruction ($n = 4$), and tibial tubercle osteotomy ($n = 4$). After the initial ACI before a revision ACI, 45 of 53 (85%) patients had a mean 2.4 subsequent surgical procedures (range, 1-6 procedures; mostly arthroscopic surgery for periosteal-related problems and adhesions). The mean time from the initial to revision ACI was 3.2 years (range, 0.3-14 years). The indications for a revision ACI included ACI graft failure ($n = 21$), progression of disease with new cartilage lesions ($n = 20$), or a new traumatic injury ($n = 12$), based on patient history, physical evaluation, magnetic resonance imaging, and/or arthroscopic findings. The progression of disease with a new cartilage lesion was defined at the time of revision ACI, the lesion being larger than that of the initial ACI ($n = 8$), the presence of new cartilage lesion without any evidence of traumatic injury ($n = 4$), and both ($n = 8$).

Presurgical Planning and Surgical Technique

ACI was performed as described in detail previously.^{20,29} First, a cartilage biopsy was performed during diagnostic

[†]Address correspondence to Tom Minas, MD, MS, Cartilage Repair Center, Paley Orthopedic and Spine Institute, St Mary's Hospital, 901 45th Street, Kimmel Building, West Palm Beach, FL 33407, USA (email: tminas@outlook.com).

^{*}Cartilage Repair Center, Brigham and Women's Hospital, Harvard Medical School, Boston, Massachusetts, USA.

[†]Sports Medicine Center, Funabashi Orthopaedic Hospital, Funabashi, Japan.

[‡]Cartilage Repair Center, Paley Orthopedic and Spine Institute, St Mary's Hospital, West Palm Beach, Florida, USA.

[§]Department of Traumatology, Semmelweis University, Budapest, Hungary.

^{||}Allegheny Health Network, Monroeville, Pennsylvania, USA.

One or more of the authors has declared the following potential conflict of interest or source of funding: B.A.M. has received hospitality payments from Arthrex, Stryker, and Biomet and education payments from Arthrex. T.M. has received education payments from Arthrex; consulting fees from Conformis, Aastrom Biosciences, and Verice; royalties from Conformis; and speaker fees from Aastrom Biosciences. AOSSM checks author disclosures against the Open Payments Database (OPD). AOSSM has not conducted an independent investigation on the OPD and disclaims any liability or responsibility relating thereto.

TABLE 2
Characteristics of Cartilage Lesions^a

Variables	Mean ± SD (Range) ^b
Cartilage lesions treated at revision ACI, No. of patients	
1	27
2	15
3	8
4	3
Total defect surface area at revision ACI, cm ²	7.4 ± 4.1 (2.5-18)
Revised defect location at revision ACI, cm ²	
MFC (n = 31)	5.0 ± 2.5 (0.6-10.6)
LFC (n = 8)	4.6 ± 2.8 (1-9.4)
Trochlea (n = 18)	4.0 ± 2.2 (0.5-8)
Patella (n = 5)	4.5 ± 2.4 (1.3-7.5)
New defect location at revision ACI, cm ²	
MFC (n = 7)	3.7 ± 1.8 (1.9-6.3)
LFC (n = 2)	2.8 ± 1.8 (1.5-4)
Trochlea (n = 12)	3.0 ± 1.8 (1-7.5)
Patella (n = 8)	3.3 ± 2.3 (0.8-8)
LTP (n = 1)	3.2
MTP (n = 1)	4

^aACI, autologous chondrocyte implantation; LFC, lateral femoral condyle; LTP, lateral tibial plateau; MFC, medial femoral condyle; MTP, medial tibial plateau.

^bUnless noted otherwise.

arthroscopic surgery that confirmed that the chondral lesions were focal. After that, chondrocytes were cultured, cryopreserved, and then thawed and recultured for definitive implantation. As early as 3 to 6 weeks after biopsy, open revision ACI surgery was performed. For surgery performed before May 2007, periosteum was harvested from the proximal tibia or distal femur. After May 2007, a type I/III bilayer collagen membrane derived from porcine peritoneum and skin (Bio-Gide; Geistlich Pharma) was used in place of autologous periosteum. For the initial ACI, autologous periosteum was used in 49 patients, and collagen type I/III membrane (Bio-Gide) was used in the other 4 patients. For the revision ACI, periosteum was used in 36 patients, and collagen type I/III membrane was used in the other 17 patients. The periosteum or collagen membrane was placed on the cartilage defect and secured with multiple 6-0 Vicryl sutures (Ethicon), the suture line was waterproofed with fibrin glue (Tisseel; Baxter Biosurgery), and autologous chondrocytes were then injected underneath the membrane.

Articular comorbidities, such as malalignment and patellar maltracking, were addressed at the time of initial ACI. Tibiofemoral malalignment >2° to 3° was corrected via osteotomy of the tibia or femur, with correction of the mechanical axis to neutral or 0°. Patellofemoral maltracking was addressed with anteromedialization tibial tubercle osteotomy to centralize patellar tracking^{12,27} and proximal soft tissue balancing (lateral release, vastus medialis obliquus advancement) as necessary to centralize the extensor mechanism. During the initial ACI, 41 patients (77%) had

TABLE 3
Cartilage Procedures Before the Initial ACI, Between the Initial and Revision ACI, and During the Revision ACI^a

Procedures Related to Cartilage Lesions	Patients, n
Before the initial ACI ^b	
A/S debridement	22
MST	22
ABG	2
Internal fixation	3
Between the initial and revision ACI	
MST	3
OATS	1
Mosaic plasty	1
ABG	1
During the revision ACI	
MST	1
ABG	2

^aABG, autologous bone grafting; ACI, autologous chondrocyte implantation; A/S, arthroscopic; MST, marrow stimulation technique; OATS, osteochondral autograft transplantation.

^bSome patients have >1 procedure.

TABLE 4
Concomitant Noncartilage Procedures Performed During the Revision ACI^a

	n
Osteotomy	
Isolated TTO	4
Isolated HTO	1
Combined HTO/TTO	1
Revision ACL reconstruction	1
Revision meniscal allograft transplantation	1
Other ^b	38
No concomitant procedure	9

^aACI, autologous chondrocyte implantation; ACL, anterior cruciate ligament; HTO, high tibial osteotomy; TTO, tibial tubercle osteotomy.

^bLateral release of patellar retinaculum (n = 23), removal of hardware (n = 11), vastus medialis obliquus advancement (n = 3), trivector quad split (n = 1).

concomitant surgery (Appendix 1, available in the online version of this article). During revision ACI, 44 patients (83%) had concomitant surgery other than procedures related to cartilage lesions (Table 4). The majority of the procedures were soft tissue balancing and removal of hardware. Six patients had concomitant tibial tubercle or high tibia osteotomy, in which 3 had it for unloading new cartilage lesions, 1 had it as a revision, and the remaining 2 had it because the malalignment was realized at the time of revision ACI.

Rehabilitation

Postoperatively, patients were instructed to use a continuous passive motion machine for 6 to 8 hours daily for 6 weeks. Patients had a hinged knee brace applied for

ambulation and remained touchdown weightbearing for 6 to 8 weeks, with gradual progression to full weightbearing by 10 to 12 weeks. Patients were allowed to return to most activities of daily living after 3 months and to noncontact, noncutting functional activities after 4 to 6 months, including biking, treadmill walking, and progression to an elliptical trainer. After 12 to 14 months, patients' activities were progressed to in-line jogging. Full activities were allowed after 14 to 18 months.

Failure Definition

The outcome of failure after revision ACI was defined as revision cartilage repair or conversion to arthroplasty for persistent or recurrent symptoms in conjunction with magnetic resonance imaging and/or arthroscopic evidence of graft delamination, inadequate fill, or degeneration requiring additional surgical treatment. Failure after ACI was defined as that attributed to (1) ACI graft alone (including delamination or biological failure to form adequate tissue or fibrous or fibrocartilaginous tissue), (2) progression of disease (with the lesion size of revision ACI being larger than that of the initial ACI and/or with the development of new cartilage lesions without any evidence of traumatic injury), and (3) a traumatic event.

Survival Analysis and Clinical Outcome Assessment

The survival rate was evaluated with the Kaplan-Meier method, with failure as the endpoint. Additionally, the survival rates of individual revised ACI grafts were assessed when cases were considered failures and patients proceeded to prosthetic arthroplasty or revision cartilage repair surgery. Patients were evaluated with the use of the modified Cincinnati Knee Rating Scale (Appendix 2, available online),²⁵ the Western Ontario and McMaster Universities Osteoarthritis Index (WOMAC),² the visual analog scale, and the 36-Item Short Form Health Survey (SF-36).⁵ Patients also answered questions regarding their self-rated knee function and satisfaction with the procedure. Scores were gathered pre- and postoperatively during an office visit or by mailed questionnaire. A subanalysis was performed by sex, age (<40 vs \geq 40 years), body mass index (<30 vs \geq 30 kg/m², technically considered a definition of obesity according to World Health Organization recommendations³⁶), cartilage defect size (<4.5 vs \geq 4.5 cm²), whether combined osteotomy occurred, membrane cover at the revision ACI (periosteum vs collagen [Biogide]), the presence of any evidence of healed graft at revision ACI, and reason for failure. Additionally, we analyzed whether the presence of a cartilage repair procedure before an initial ACI had any significant influence after the revision ACI. For this additional analysis, patients who had undergone arthroscopic debridement alone were not considered to have undergone a cartilage repair procedure.

Radiographic Evaluation

Standing long alignment radiographs were obtained, including hip/knee/ankle, standing anteroposterior, Rosenberg, and

lateral radiographs. Anteroposterior and lateral radiographs were scored in accordance with the Kellgren-Lawrence (K-L) grade¹⁹ to evaluate the progression of osteoarthritis before and after the revision ACI surgery. Cases that failed after the revision ACI were evaluated separately.

Statistical Analysis

All statistical analyses were performed with Stata (v 13; StataCorp LP). The level of significance was set a priori at $P < .05$. The Wilcoxon signed rank test was used to compare differences in functional scores (obtained from the visual analog scale, WOMAC, SF-36, and modified Cincinnati) between the time points (ie, before the revision ACI and at the latest follow-up). Kaplan-Meier survival curves were used for survival analyses, with failure of the revision ACI as the endpoint, followed by a log-rank analysis. Differences in patient demographics and characteristics between groups were compared with the unpaired t test or Mann-Whitney U test for continuous data, based on the distribution of data determined by the Shapiro-Wilk test. For categorical data, Fisher exact test or Pearson chi-square was used as appropriate.

RESULTS

Survival Analysis

Overall, survival was 71% (95% CI, 57%-82%) and 53% (95% CI, 37%-67%) at 5 and 10 years, respectively (Figure 1). Subanalysis per sex, age, body mass index, cartilage defect size, whether combined osteotomy occurred, membrane cover, and presence of any evidence of healed graft at revision ACI failed to determine a significant difference in survival rate (Table 5). A better survival rate was found in the patients without previous cartilage repair procedures before the initial ACI than in those with previous cartilage repair procedures before the initial ACI, but it failed to reach statistical significance: 81% (95% CI, 60-90) versus 62% (95% CI, 43-77) at 5 years and 64% (95% CI, 39-81) versus 42% (95% CI, 22-61) at 10 years ($P = .0958$) (Figure 2).

Functional Outcomes and Patient Satisfaction

Of 27 patients without failure, all functional scores significantly improved when compared with preoperative scores (Table 6). Of those, approximately 80% of the patients were satisfied with the revision ACI and answered that they would choose the same surgery and that the results of their knee surgery were good or excellent (Table 7).

Radiographic Evaluation

Of 28 knees that did not fail during the follow-up period, 18 (27%) were available to undergo review of follow-up radiographs at a mean 5.1 years postoperatively with a minimum of 2 years' follow-up (range, 2-13 years). There was no significant increase in the level of osteoarthritis based

TABLE 5
Subanalysis of Survival Rate at 5 and 10 Years^a

	Percentage (95% CI)			P Value
Sex	Male (n = 26)		Female (n = 27)	.6920
5 y	88 (66-96)		59 (39-75)	
10 y	51 (25-72)		55 (34-71)	
Age at revision ACI	<40 (n = 31)		≥40 (n = 22)	.3436
5 y	67 (48-81)		77 (54-90)	
10 y	46 (27-64)		64 (37-82)	
BMI	<30 (n = 39)		≥30 (n = 14)	.5850
5 y	72 (55-84)		73 (44-89)	
10 y	49 (29-66)		65 (35-84)	
Defect size	<4.5 cm ² (n = 15)		≥4.5 cm ² (n = 38)	.068
5 y	53 (26-74)		79 (62-89)	
10 y	46 (20-68)		56 (36-72)	
Osteotomy	Yes (n = 32)		No (n = 21)	.2812
5 y	78 (59-89)		62 (38-79)	
10 y	63 (41-79)		41 (20-61)	
Cover membrane	Periosteum (n = 36)		Biogide (n = 17)	.4010
5 y	67 (49-80)		82 (55-94)	
10 y	50 (33-65)		66 (26-88) ^b	
Presence of cartilage repair procedures before the initial ACI	Yes (n = 26)		No (n = 27)	.0958
5 y	62 (43-77)		81 (60-91)	
10 y	42 (22-61)		64 (39-81)	
Evidence of any healed grafts	Yes (n = 22)		No (n = 31)	.7086
5 y	64 (40-80)		77 (58-88)	
10 y	51 (27-70)		55 (33-72)	
Failure reason	Graft alone	Progression	Trauma	.6733
5 y	(n = 21)	(n = 20)	(n = 12)	
10 y	66 (42-82)	70 (45-85)	83 (48-96)	
	54 (29-73)	50 (24-70)	60 (24-83)	

^aACI, autologous chondrocyte implantation; BMI, body mass index (kg/m²).

^bSurvival rate at 8 years.

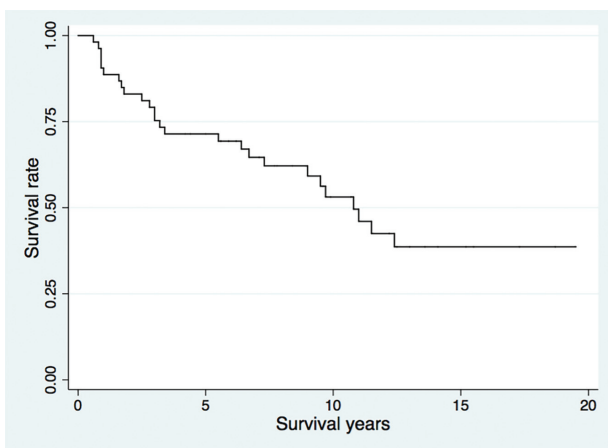


Figure 1. Kaplan-Meier survival curve (N = 53).

on K-L grade before and after revision ACI (mean ± SD: 1.9 ± 0.5 preoperatively and 2.1 ± 0.6 postoperatively, P = .1573). We found no increase in K-L grade in 16 patients and a 1-grade increase in 2 patients.

Of 11 knees that failed and had revision cartilage repair procedures, 6 patients were available for clinical review of

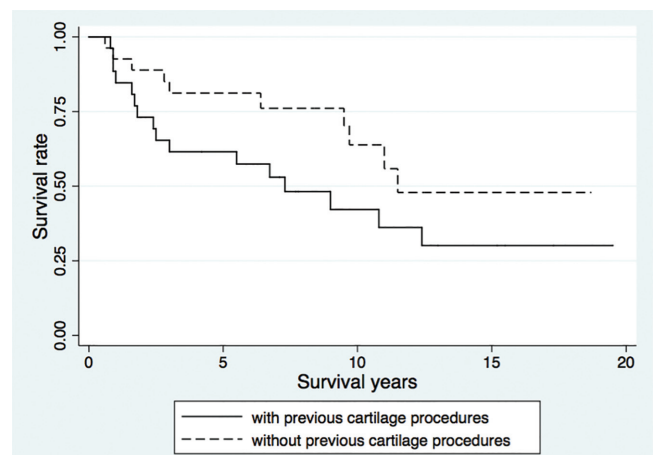


Figure 2. Kaplan-Meier survival curve. Survival rate with (n = 26) and without (n = 27) previous cartilage procedures before the initial autologous chondrocyte implantation.

repeat radiographs at a mean 4.1 years (range, 1.1-7.6 years). Of these 6 patients, 1 had a 1-grade increase in K-L, and the others remained the same.

TABLE 6
Preoperative and Final Follow-up Clinical
Outcomes in Patients With Retained Grafts^a

Rating System	Preoperative	Final Follow-up	P Value
Modified Cincinnati	3.5 ± 1.3	4.4 ± 1.6	.0378
VAS	5.9 ± 1.3	4.3 ± 1.4	<.001
WOMAC			
Total	44.9 ± 13.3	34.5 ± 14.7	<.001
Pain	9.9 ± 3.5	7.5 ± 3.2	.0012
Stiffness	4 ± 1.4	2.8 ± 1.7	.0010
Function	31.1 ± 9.2	24.1 ± 10.3	<.001
SF-36			
PCS	41.6 ± 5.5	44.5 ± 5.9	.0393
MCS	36.2 ± 5.2	41.8 ± 7.3	<.001

^aValues are presented as mean ± SD. MCS, mental component score; PCS, physical component score; SF-36, 36-Item Short Form Health Survey; VAS, visual analog scale; WOMAC, Western Ontario and McMaster Universities Osteoarthritis Index.

Treatment Failures

Within the study period, 26 patients had failure of their revision ACI procedures at a mean 4.9 years (range, 0.6-11.5 years). Three failures occurred because of a traumatic event. Overall, 15 of 53 patients (28%) underwent arthroplasty at a mean 4.6 years (range, 0.6-12.4 years) postoperatively, and 11 (21%) underwent revision cartilage repair surgery at a mean 5.4 years (range, 0.9-9.7 years) postoperatively: re-revision ACI for 4 patients (ACI-P in 2 and ACI-C in 2), osteochondral allograft transplantation for 4, osteochondral autograft transplantation for 1, chondroplasty for 1, and autologous cancellous bone grafting for 1. All patients who failed revision ACI were successfully treated and had improvement in pain and joint function after surgery.

On further analysis, of 9 initial ACI failures attributed to failure of the graft (delamination in 5 and biological in 4), the most common reason for failure after revision ACI was also ACI graft failure (n = 7), including biological failure (n = 6). Similarly, of the 11 initial ACI failures attributed to progression, the reason for failure after revision ACI was also progression (n = 8).

Subsequent Surgical Procedures

Overall, 39 patients (74%) required a mean 1.8 subsequent surgical procedures after the revision ACI (Table 8), of which 99% were performed arthroscopically. The most common requirements for subsequent surgery were related to ACI-P graft (18 patients, 30 procedures), including 14 cases of periosteal hypertrophy, 1 case of periosteal delamination, and 3 cases of both. When the use of periosteal membrane (ACI-P) was compared with collagen membrane (ACI-C) at the revision ACI, the rate of chondroplasty with excision of hypertrophy required after ACI-P was approximately twice as high as that after ACI-C owing to primarily periosteal hypertrophy. Non-graft related reasons for subsequent surgery included arthrofibrosis in 17 patients, partial meniscectomy in 5, painful suture removal in 1, and

TABLE 7
Satisfaction Survey at the Latest Follow-up

Question	Graft In Situ at the Latest Follow-up, % (n = 27)
Compared with before each surgery, how would you rate your operated joint now?	
Better	71.4
About the same	25
Worse	3.6
What is your overall satisfaction level with the joint surgery?	
Satisfied	78.6
Neutral	14.3
Dissatisfied	7.1
If you could go back in time and make the decision again, would you choose to have your joint surgery?	
Yes	82.1
Uncertain	17.9
No	0
How would you rate the results of your joint surgery?	
Good/excellent	82.1
Fair	14.3
Poor	3.6

high tibial osteotomy in 1. High tibial osteotomy was performed in a staged manner because new lesions in the medial femoral condyle and medial tibial plateau were found at the revision ACI when revised transplantation was necessary for a trochlear lesion. Of the 39 knees (54%) requiring subsequent surgery, 21 proceeded to become failure cases.

DISCUSSION

In this retrospective review of 53 patients who underwent revision ACI for failed initial ACI, our results showed survival rates of 71% at 5 years and 53% at 10 years postoperatively. Patients with retained grafts showed significant improvement in pain and function over a long-term follow-up with a high level of satisfaction. Overall, 72% of patients avoided a prosthetic arthroplasty. The overall survival rate for revision ACI was comparable with or inferior to the previously reported results of an initial ACI, with similar mid- to long-term follow-up.^{1,3,4,23,31,32,34,41} When we consider that our cohort included complex and salvage knees and that patients desired strongly to maintain their biological knees, the outcomes of the revision ACI for failed ACI was acceptable, and revision ACI may be an option for failed ACI. To our knowledge, this was the first study that reported long-term results with a large cohort after revision ACI for failed ACI.

A prior study reported on acceptable outcomes of revision ACI over midterm follow-up in patients who had failed an initial ACI. Vijayan et al,⁴³ from Stanmore, United Kingdom, reported on 22 patients who had revision ACI

TABLE 8
Comparison of Subsequent Surgical Procedures Between Periosteum and Collagen Membrane After a Revision ACI^a

	No. of Patients (Total Procedures), %		
	ACI-P (n = 36)	ACI-C (n = 17)	Total (N = 53)
ACI graft related			
Chondroplasty	18 (30), 50	4 (4), 24	22 (34), 42
Hypertrophy	14 (21)	2 (2)	16 (23)
Delamination	1 (1)	2 (2)	3 (3)
Hypertrophy and delamination	3 (8)	0 (0)	3 (8)
Microfracture (<25% of graft)	3 (3), 8	0 (0), 0	3 (3), 6
ACI graft unrelated			
Lysis	10 (15), 28	7 (11), 41	17 (26), 32
A/S meniscectomy	4 (4), 11	1 (1), 6	5 (5), 9
Removal of painful suture	1 (1), 3	0 (0), 0	1 (1), 2
HTO	1 (1), 3	0 (0), 0	1 (1), 2
No subsequent procedures	8 (—), 22	6 (—), 35	14 (—), 26

^aACI, autologous chondrocyte implantation; ACI-C, autologous chondrocyte implantation with collagen membrane; ACI-P, autologous chondrocyte implantation with periosteum; A/S, arthroscopic; HTO, high tibial osteotomy.

or matrix-assisted ACI of the primary ACI or matrix-assisted ACI grafts (mean defect size, 446.6 mm²; location: MFC, n = 11; LFC, n = 1; patella, n = 8; trochlea, n = 1) at a mean 5.4 years postoperatively (range, 1.3-10.9 years). They found that the clinical outcomes improved significantly and that 63% of patients reported good or excellent clinical outcomes. Two patients (9%) underwent conversion to a prosthetic arthroplasty, and 1 patient had a third revision ACI. Our observations were taken over a much longer follow-up period, a mean 11.2-year follow-up. It is difficult to make direct comparisons with their study because of the difference in generation of the ACI (technique and material used during surgery). In addition, unlike the study by Vijayan et al, our cohort included the treatment of new lesions other than the originally implanted lesions at the time of revision ACI. This leads us to believe that the longer-term follow-up, twice as long, allowed us to identify those patients who would have progression of disease not identified in the Stanmore series because of the shorter study period. In addition, our study included radiographic findings that showed no significant increase of osteoarthritis based on K-L grading (*P* = .1573) for the midterm.

Survivorship after revision ACI in our study (71% at 5 years and 53% at 10 years) was comparable with the Stanmore series and similar to previously reported primary ACI survivorship series that varied between 51% and 83% at 10 years.^{4,31,33-35} Nawaz et al³⁴ reported that degenerative change and ≥1 prior cartilage regenerative procedures had a significant negative effect on survivorship after ACI. Our cohort had multiple previous surgical procedures related to cartilage repair, including the initial ACI. The radiographic stage of osteoarthritis, K-L grade, at the time of revision ACI was 1.9, which could account for inferior survivorship. Horton et al¹⁶ also reported on the inferior outcome of revision osteochondral allograft transplantation (OCA) for failed primary OCA as compared with primary OCA. Despite this, >80% of the patients who were

successfully treated with revision ACI reported their knees as good/excellent, with a high level of satisfaction.

The survivorship at 5 years after revision ACI with the ACI-C was superior to the ACI-P (82% vs 67%) but failed to show a statistical difference. Longer follow-up is necessary to determine if the use of collagen membrane at revision surgery improves the outcome after revision ACI, as a prior study demonstrated that the quality of regenerative cartilage tissue produced in ACI-C was better than that in ACI-P.²⁴

The presence of cartilage repair procedures before an initial ACI, primarily marrow stimulation techniques in our study, negatively influenced the survival rate after revision ACI, although it did not reach statistical difference. This observation is in line with previous studies that evaluated clinical outcomes after primary ACI.^{21,28,34,39} Failure of ACI after marrow stimulation techniques is thought to be due to alteration of the osteochondral unit, with violation of the subchondral bone leading to intralesional osteophyte formation, cysts, and sclerosis of the subchondral plate,^{9,13} which can negatively affect the integration of regenerative cartilage surface tissue. Our results suggest that an initial cartilage repair procedure may negatively affect the results of a subsequent one, which surgeons should take into consideration. A patient with a prior cartilage repair procedure may have altered subchondral bone. Our preferred method of dealing with this is to remove the abnormal sclerotic bone, intralesional osteophytes, or cystic lesions and restore the osseous and cartilaginous tissue (osteochondral unit) with the ACI “sandwich” technique.^{30,44} Prior studies showed that predictors for successful treatment after ACI are based on patient demographics,^{11,18} the biological nature of the repair tissue, and synovial fluid.^{17,45} Our results indicated that alteration of the subchondral bone may determine the next treatment after failed ACI; revision ACI, sandwich ACI, allograft, or prosthesis (Figure 3).

The subsequent surgical procedure rate observed in this study appears higher (74%) than the generally reported

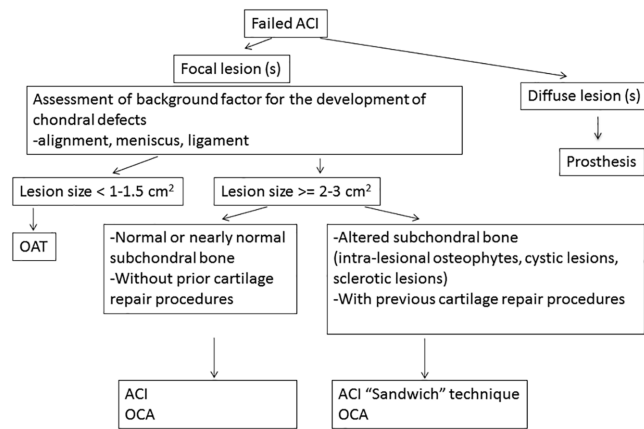


Figure 3. Recommendation of treatment algorithm after failed ACI. ACI, autologous chondrocyte implantation; OAT, osteochondral autograft transplantation; OCA, osteochondral allograft transplantation.

reoperation rate of 13% to 68% after ACI.^{1,3,4,23,31-33} However, the majority of the ACI graft-related procedures were performed because of periosteal hypertrophy, which decreased after the use of collagen membrane.¹⁴ In addition, there were multiple grafts per knee, unlike other studies, increasing the likelihood of periosteal hypertrophy per knee. Subsequent procedures were primarily performed arthroscopically and managed uneventfully.

Interestingly, patients who failed their initial ACI because of graft failure were likely to fail primarily because of graft failure. Likewise, patients who failed their initial ACI owing to progression of disease were likely to fail owing to progression of disease. Further investigation will be of interest to see what specific factors are associated with the specific failure reason after revision ACI. Nevertheless, we believe that these results are helpful to discuss with patients before determining and proceeding to the revision ACI and to manage their expectations.

ACI is the most expensive cartilage repair procedure. The cost-effectiveness of revision ACI needs to be determined, as that of initial ACI has been previously studied.^{7,22,26} Specifically, the procedure was determined to be very cost-effective owing to its long-term durability and marked clinical improvement in pain and function.^{31,40,41} ACI is also comparable with and more cost-effective than other health care interventions, such as those for hypertension and diabetes.²⁶

The strength of our study included a single-surgeon series with the same indications and postoperative rehabilitation. However, there were several limitations. First, this study was a case series without a control group. However, a control group is difficult to find in light of a failed ACI, with disabling baseline preoperative symptoms. Second, the majority of the patients in our study underwent concomitant procedures to treat background comorbidities that needed to be addressed at the time of surgery. Third, this cohort included motivated patients who wished to maintain their biological knees. However, patient motivation should be one of the inclusion criteria for ACI because

patients are encouraged to follow strict postoperative protocols to prevent early graft failure. Finally, we were unable to evaluate all radiographs despite our efforts, given the destruction of baseline radiographs after conversion to digital films in the early cases.

In conclusion, our results demonstrated that revision ACI provides acceptable outcomes, although they appeared comparable to or inferior to generally reported results after primary ACI, in our cohort of 53 patients who had failed primary ACI. Eventually, 72% of patients could avoid prosthetic arthroplasty at a mean 11.2 years' follow-up after failure of an initial ACI. Revision ACI may be an option for young patients after failed primary ACI, particularly in patients without previous cartilage repair procedures and those who desire to maintain their native knees.

REFERENCES

1. Aldrian S, Zak L, Wondrasch B, et al. Clinical and radiological long-term outcomes after matrix-induced autologous chondrocyte transplantation: a prospective follow-up at a minimum of 10 years. *Am J Sports Med.* 2014;42(11):2680-2688.
2. Bellamy N, Buchanan WW, Goldsmith CH, Campbell J, Stitt LW. Validation study of WOMAC: a health status instrument for measuring clinically important patient relevant outcomes to antirheumatic drug therapy in patients with osteoarthritis of the hip or knee. *J Rheumatol.* 1988;15(12):1833-1840.
3. Bentley G, Biant LC, Vijayan S, Macmull S, Skinner JA, Carrington RW. Minimum ten-year results of a prospective randomised study of autologous chondrocyte implantation versus mosaicplasty for symptomatic articular cartilage lesions of the knee. *J Bone Joint Surg Br.* 2012;94(4):504-509.
4. Biant LC, Bentley G, Vijayan S, Skinner JA, Carrington RW. Long-term results of autologous chondrocyte implantation in the knee for chronic chondral and osteochondral defects. *Am J Sports Med.* 2014;42(9):2178-2183.
5. Brazier JE, Harper R, Jones NM, et al. Validating the SF-36 health survey questionnaire: new outcome measure for primary care. *BMJ.* 1992;305(6846):160-164.
6. Brittberg M, Lindahl A, Nilsson A, Ohlsson C, Isaksson O, Peterson L. Treatment of deep cartilage defects in the knee with autologous chondrocyte transplantation. *N Engl J Med.* 1994;331(14):889-895.
7. Clar C, Cummins E, McIntyre L, et al. Clinical and cost-effectiveness of autologous chondrocyte implantation for cartilage defects in knee joints: systematic review and economic evaluation. *Health Technol Assess.* 2005;9(47):1-82.
8. Dell'Accio F, Vincent T. Joint surface defects: clinical course and cellular response in spontaneous and experimental lesions. *Eur Cell Mater.* 2010;20(210):7.
9. Demange MK, Minas T, von Keudell A, Sodha S, Bryant T, Gomoll AH. Intralesional osteophyte regrowth following autologous chondrocyte implantation after previous treatment with marrow stimulation technique. *Cartilage.* 2017;8(2):131-138.
10. Ding C, Cicuttini F, Jones G. Tibial subchondral bone size and knee cartilage defects: relevance to knee osteoarthritis. *Osteoarthritis Cartilage.* 2007;15(5):479-486.
11. Dugard MN, Kuiper JH, Parker J, et al. Development of a tool to predict outcome of autologous chondrocyte implantation. *Cartilage.* 2017;8(2):119-130.
12. Fulkerson JP. Anteromedialization of the tibial tuberosity for patellofemoral malalignment. *Clin Orthop Relat Res.* 1983;177:176-181.
13. Gomoll AH, Madry H, Knutsen G, et al. The subchondral bone in articular cartilage repair: current problems in the surgical management. *Knee Surg Sports Traumatol Arthrosc.* 2010;18(4):434-447.
14. Gomoll AH, Probst C, Farr J, Cole BJ, Minas T. Use of a type I/III bilayer collagen membrane decreases reoperation rates for symptomatic

- hypertrophy after autologous chondrocyte implantation. *Am J Sports Med.* 2009;37(suppl 1):20S-23S.
15. Gracitelli GC, Meric G, Pulido PA, McCauley JC, Bugbee WD. Osteochondral allograft transplantation for knee lesions after failure of cartilage repair surgery. *Cartilage.* 2015;6(2):98-105.
 16. Horton MT, Pulido PA, McCauley JC, Bugbee WD. Revision osteochondral allograft transplantations: do they work? *Am J Sports Med.* 2013;41(11):2507-2511.
 17. Hulme CH, Wilson EL, Peffers MJ, et al. Autologous chondrocyte implantation-derived synovial fluids display distinct responder and non-responder proteomic profiles. *Arthritis Res Ther.* 2017;19(1):150.
 18. Jungmann PM, Salzmann GM, Schmal H, Pestka JM, Sudkamp NP, Niemeyer P. Autologous chondrocyte implantation for treatment of cartilage defects of the knee: what predicts the need for reintervention? *Am J Sports Med.* 2012;40(1):58-67.
 19. Kellgren JH, Lawrence JS. Radiological assessment of rheumatoid arthritis. *Ann Rheum Dis.* 1957;16(4):485-493.
 20. King PJ, Bryant T, Minas T. Autologous chondrocyte implantation for chondral defects of the knee: indications and technique. *J Knee Surg.* 2002;15(3):177-184.
 21. Lamplot JD, Schafer KA, Matava MJ. Treatment of failed articular cartilage reconstructive procedures of the knee: a systematic review. *Orthop J Sports Med.* 2018;6(3):2325967118761871.
 22. Lindahl A, Brittberg M, Peterson L. Health economics benefits following autologous chondrocyte transplantation for patients with focal chondral lesions of the knee. *Knee Surg Sports Traumatol Arthrosc.* 2001;9(6):358-363.
 23. Martincic D, Radosavljevic D, Drobic M. Ten-year clinical and radiographic outcomes after autologous chondrocyte implantation of femoral condyles. *Knee Surg Sports Traumatol Arthrosc.* 2014;22(6):1277-1283.
 24. McCarthy HS, Roberts S. A histological comparison of the repair tissue formed when using either Chondrogide((R)) or periosteum during autologous chondrocyte implantation. *Osteoarthritis Cartilage.* 2013;21(12):2048-2057.
 25. Micheli LJ, Browne JE, Erggelet C, et al. Autologous chondrocyte implantation of the knee: multicenter experience and minimum 3-year follow-up. *Clin J Sport Med.* 2001;11(4):223-228.
 26. Minas T. Chondrocyte implantation in the repair of chondral lesions of the knee: economics and quality of life. *Am J Orthop (Belle Mead, N.J.).* 1998;27(11):739-744.
 27. Minas T, Bryant T. The role of autologous chondrocyte implantation in the patellofemoral joint. *Clin Orthop Relat Res.* 2005;436:30-39.
 28. Minas T, Gomoll AH, Rosenberger R, Royce RO, Bryant T. Increased failure rate of autologous chondrocyte implantation after previous treatment with marrow stimulation techniques. *Am J Sports Med.* 2009;37(5):902-908.
 29. Minas T, Ogura T, Bryant T. Autologous chondrocyte implantation. *JBJS Essent Surg Tech.* 2016;6(2):e24.
 30. Minas T, Ogura T, Headrick J, Bryant T. Autologous chondrocyte implantation "sandwich" technique compared with autologous bone grafting for deep osteochondral lesions in the knee. *Am J Sports Med.* 2018;46(2):322-332.
 31. Minas T, Von Keudell A, Bryant T, Gomoll AH. The John Insall Award: a minimum 10-year outcome study of autologous chondrocyte implantation. *Clin Orthop Relat Res.* 2014;472(1):41-51.
 32. Moradi B, Schonit E, Nierhoff C, et al. First-generation autologous chondrocyte implantation in patients with cartilage defects of the knee: 7 to 14 years' clinical and magnetic resonance imaging follow-up evaluation. *Arthroscopy.* 2012;28(12):1851-1861.
 33. Moseley JB Jr, Anderson AF, Browne JE, et al. Long-term durability of autologous chondrocyte implantation: a multicenter, observational study in US patients. *Am J Sports Med.* 2010;38(2):238-246.
 34. Nawaz SZ, Bentley G, Briggs TW, et al. Autologous chondrocyte implantation in the knee: mid-term to long-term results. *J Bone Joint Surg Am.* 2014;96(10):824-830.
 35. Niemeyer P, Porichis S, Steinwachs M, et al. Long-term outcomes after first-generation autologous chondrocyte implantation for cartilage defects of the knee. *Am J Sports Med.* 2014;42(1):150-157.
 36. Obesity: preventing and managing the global epidemic. Report of a WHO consultation. *World Health Organ Tech Rep Ser.* 2000;894:1-253.
 37. Ogura T, Bryant T, Minas T. Long-term outcomes of autologous chondrocyte implantation in adolescent patients. *Am J Sports Med.* 2017;45(5):1066-1074.
 38. Ogura T, Mosier BA, Bryant T, Minas T. A 20-year follow-up after first-generation autologous chondrocyte implantation. *Am J Sports Med.* 2017;45(12):2751-2761.
 39. Pestka JM, Bode G, Salzmann G, Sudkamp NP, Niemeyer P. Clinical outcome of autologous chondrocyte implantation for failed microfracture treatment of full-thickness cartilage defects of the knee joint. *Am J Sports Med.* 2012;40(2):325-331.
 40. Peterson L, Minas T, Brittberg M, Nilsson A, Sjogren-Jansson E, Lindahl A. Two- to 9-year outcome after autologous chondrocyte transplantation of the knee. *Clin Orthop Relat Res.* 2000;374:212-234.
 41. Peterson L, Vasiliadis HS, Brittberg M, Lindahl A. Autologous chondrocyte implantation: a long-term follow-up. *Am J Sports Med.* 2010;38(6):1117-1124.
 42. Rosenberger RE, Gomoll AH, Bryant T, Minas T. Repair of large chondral defects of the knee with autologous chondrocyte implantation in patients 45 years or older. *Am J Sports Med.* 2008;36(12):2336-2344.
 43. Vijayan S, Bentley G, Rahman J, Briggs TW, Skinner JA, Carrington RW. Revision cartilage cell transplantation for failed autologous chondrocyte transplantation in chronic osteochondral defects of the knee. *Bone Joint J.* 2014;96(1):54-58.
 44. von Keudell A, Gomoll AH, Bryant T, Minas T. Spontaneous osteonecrosis of the knee treated with autologous chondrocyte implantation, autologous bone-grafting, and osteotomy: a report of two cases with follow-up of seven and nine years. *J Bone Joint Surg Am.* 2011;93(24):e149.
 45. Wright KT, Kuiper JH, Richardson JB, Gallacher P, Roberts S. The absence of detectable ADAMTS-4 (aggrecanase-1) activity in synovial fluid is a predictive indicator of autologous chondrocyte implantation success. *Am J Sports Med.* 2017;45(8):1806-1814.